



RESENTING CLINICAL SIGNS

DATE History: Wheezing. No cough. Previous radiographs suggestive of cardiomegaly. No murmur. Overweight.

6/22/22

ECHOCARDIOGRAPHIC FINDINGS

2D, M-mode, and Doppler study.

PERFORMED BY:

Dr. Meredith Swart

INTERPRETED BY

Keith Blass, DVM,
MS, DACVIM
(Cardiology)

Left atrial size is normal. There is prolapse of the anterior mitral valve leaflet, though no evidence of mitral regurgitation is seen. Left ventricular dimensions are normal. Left ventricular systolic function is normal. The aorta and aortic valve are normal. Right atrial and right ventricular dimensions are normal. The tricuspid valve is normal. The pulmonary artery and pulmonic valve are normal. No pericardial effusion or cardiac masses are seen.

LA - 16.5 mm
LVIDd - 17.7 mm
LVIDs - 10.4 mm
FS - 41%
LVOT - 0.85 m/s
RVOT - 0.92 m/s

PATIENT

Gigi Bartley

ASSESSMENT/RECOMMENDATIONS

SPECIES

Canine

This examination demonstrates prolapse of Gigi's anterior mitral valve leaflet. While no evidence of secondary mitral regurgitation is seen, it's likely that the prolapse is a very early indicator of developing degenerative valve disease, therefore, careful monitoring for the development of a left apical heart murmur is recommended going forward.

BREED

Chihuahua

No reason for Gigi's wheezing is appreciated in this exam, and her wheezing is likely due to a primary airway issue.

No therapy is recommended based on this exam.

SEX

A recheck echocardiogram is recommended if new physical exam and/or clinical abnormalities suggestive of cardiac dysfunction develop.

FS

AGE

12 y

WEIGHT

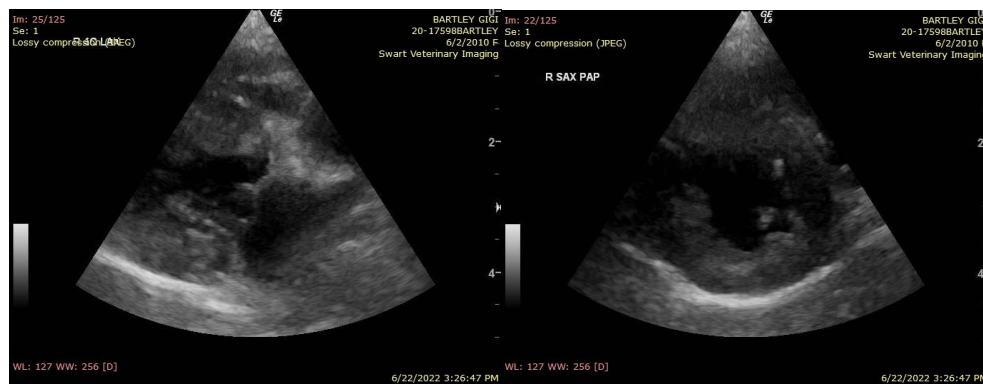
5.84 lb

HOSPITAL NAME

Swart Veterinary
Imaging

REFERRING VET

Dr. Swart



The information and recommendations provided are based on the images presented by the referring veterinarian. No evaluation can be communicated regarding pathology that was not visible in the image/video clips provided.



Thank you for this referral. If the clinical or image interpretation does not parallel your findings or if I can be of any further assistance please contact me.

DATE

6/22/22

Keith Blass, DVM, MS, DACVIM (Cardiology)
KeithBlass@gmail.com
631-804-5754

PERFORMED BY:

Dr. Meredith Swart

INTERPRETED BY

Keith Blass, DVM,
MS, DACVIM
(Cardiology)

PATIENT

Gigi Bartley

SPECIES

Canine

BREED

Chihuahua

SEX

FS

AGE

12 y

WEIGHT

5.84 lb

HOSPITAL NAME

Swart Veterinary
Imaging

REFERRING VET

Dr. Swart